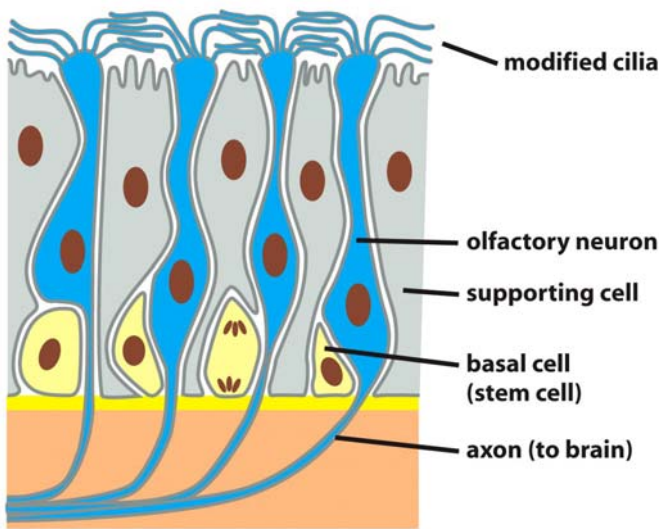
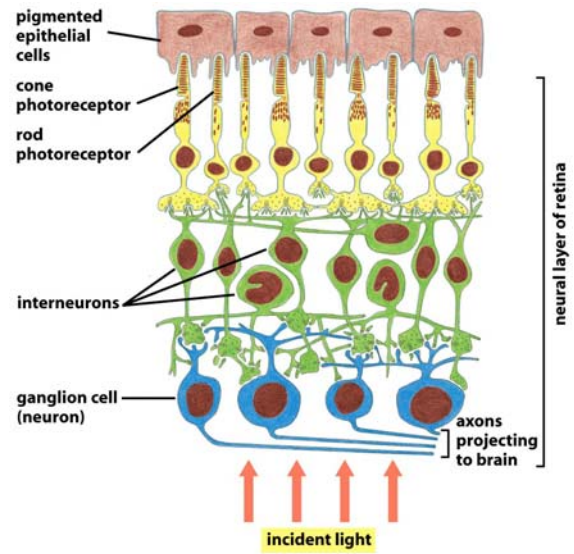


Neuroepiteli



Epitelio olfattivo

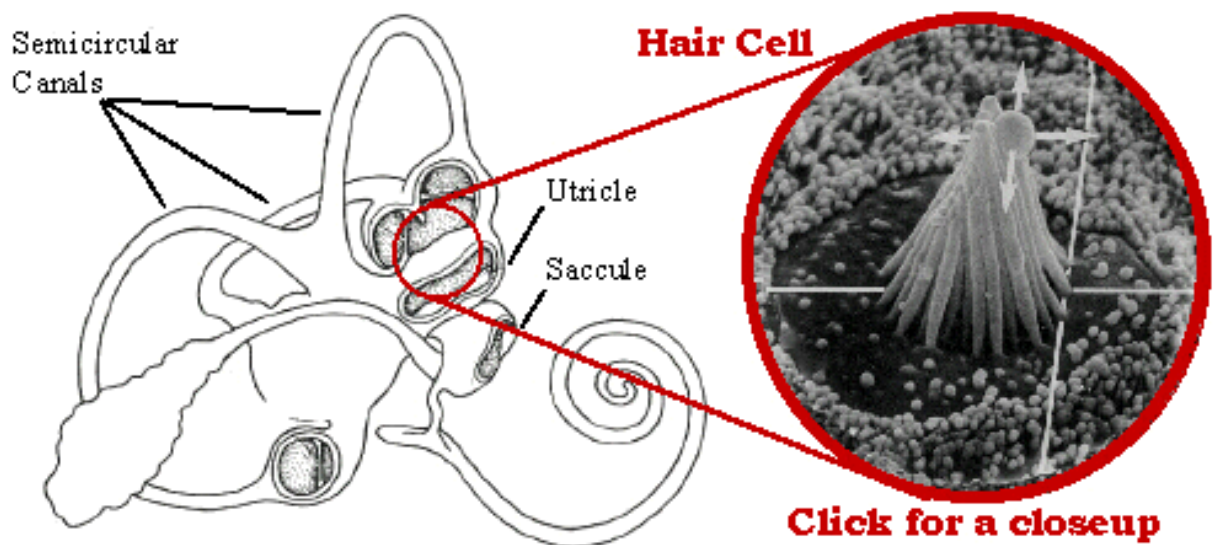
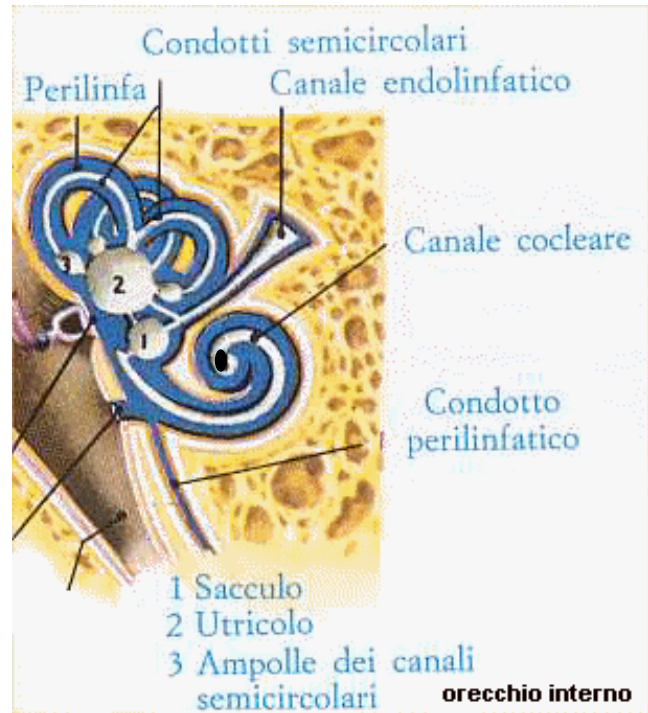
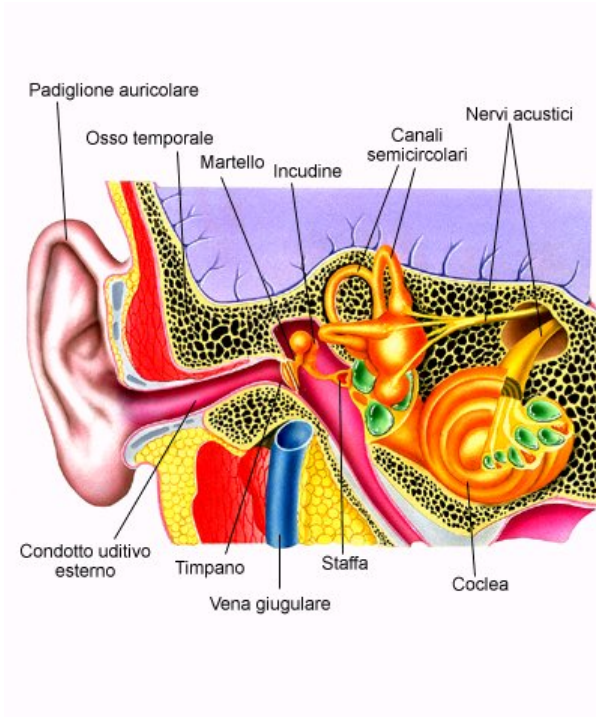


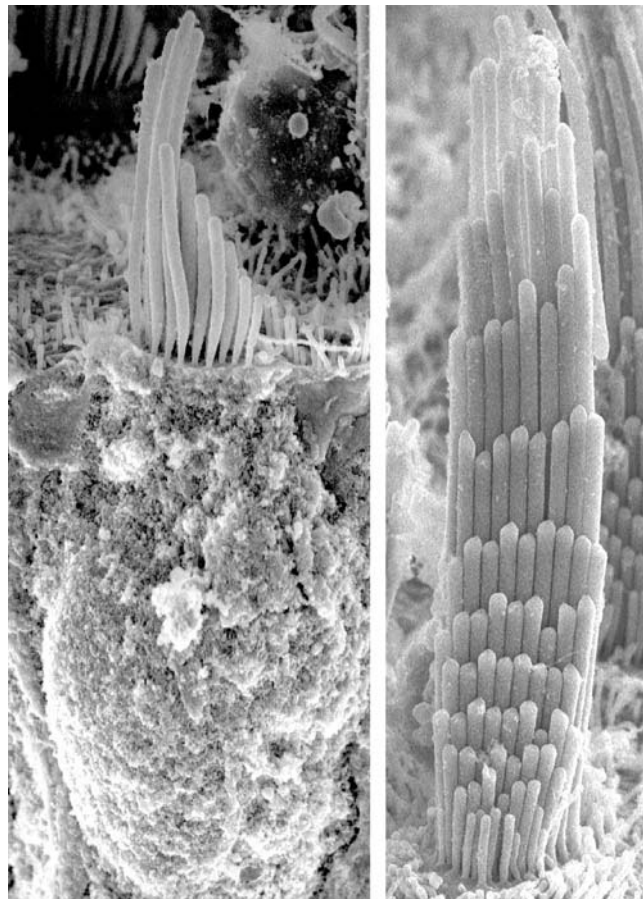
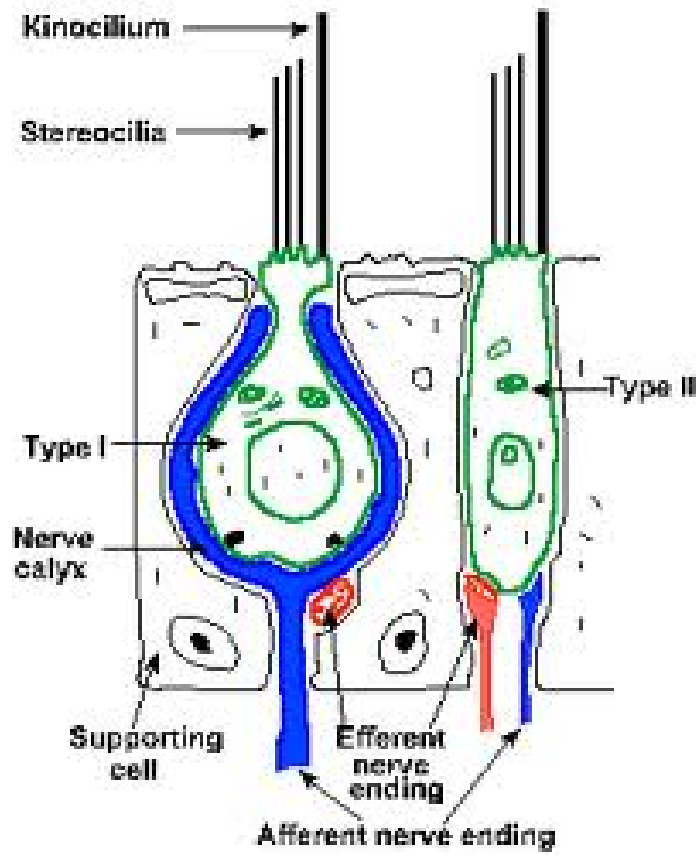
Coni e bastoncelli della retina

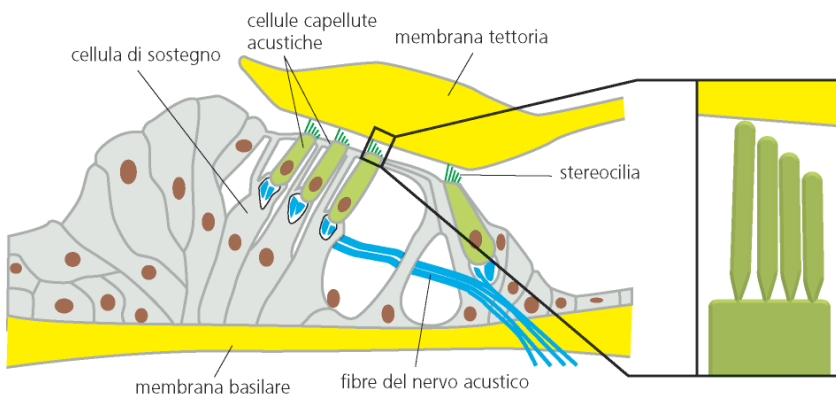
Epiteli sensoriali

- **Epitelio delle creste ampollari, delle macule di utricolo e sacculo, dell'organo del Corti**
- **Bottoncini gustativi**
- **Neuromasti**

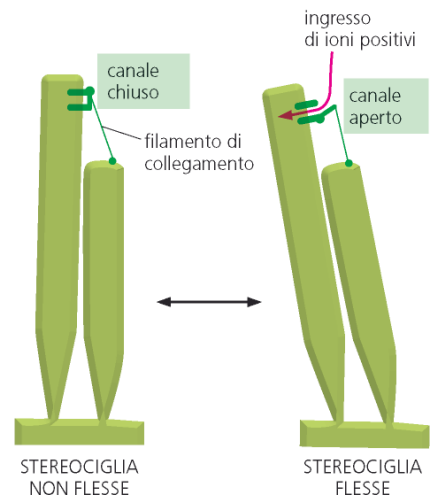
ORECCHIO



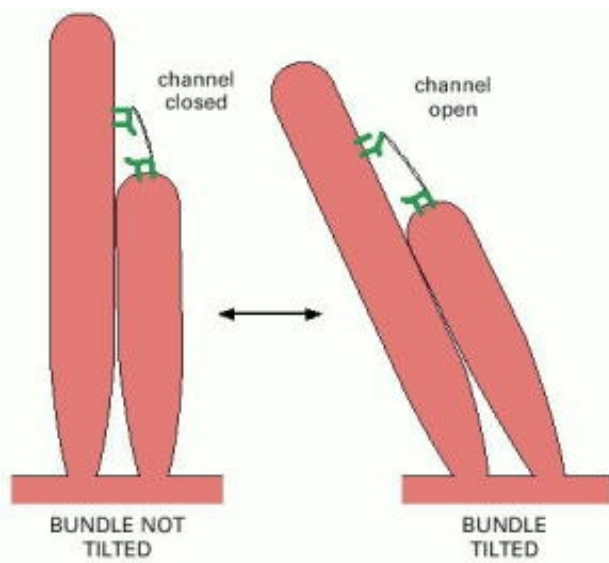




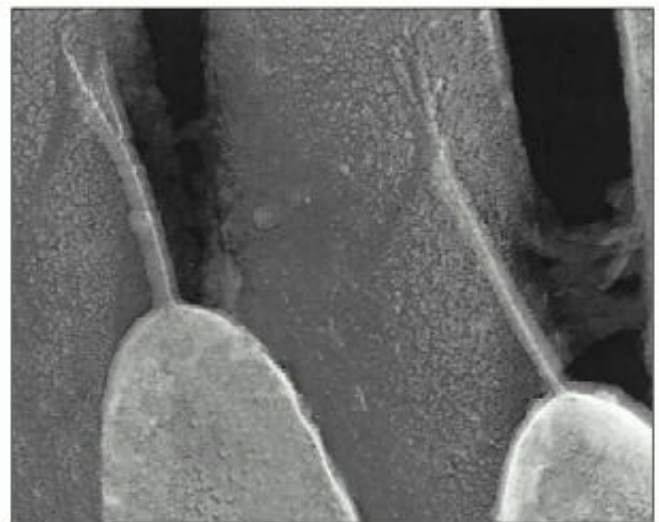
(A)



(B)

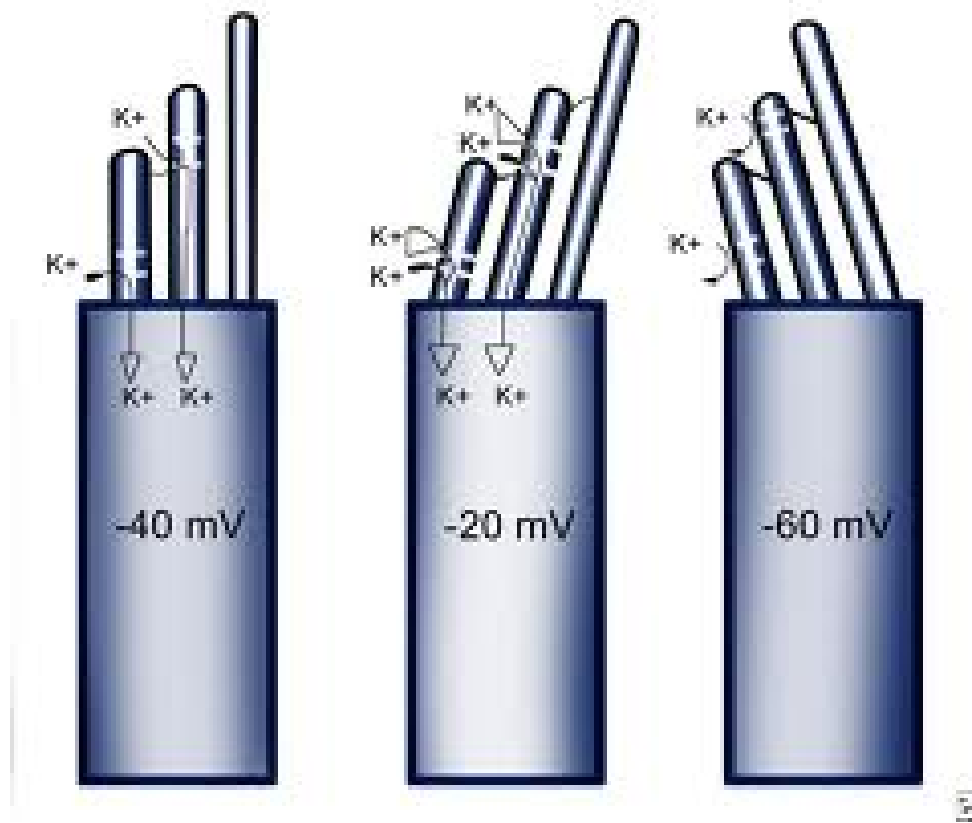


(A)

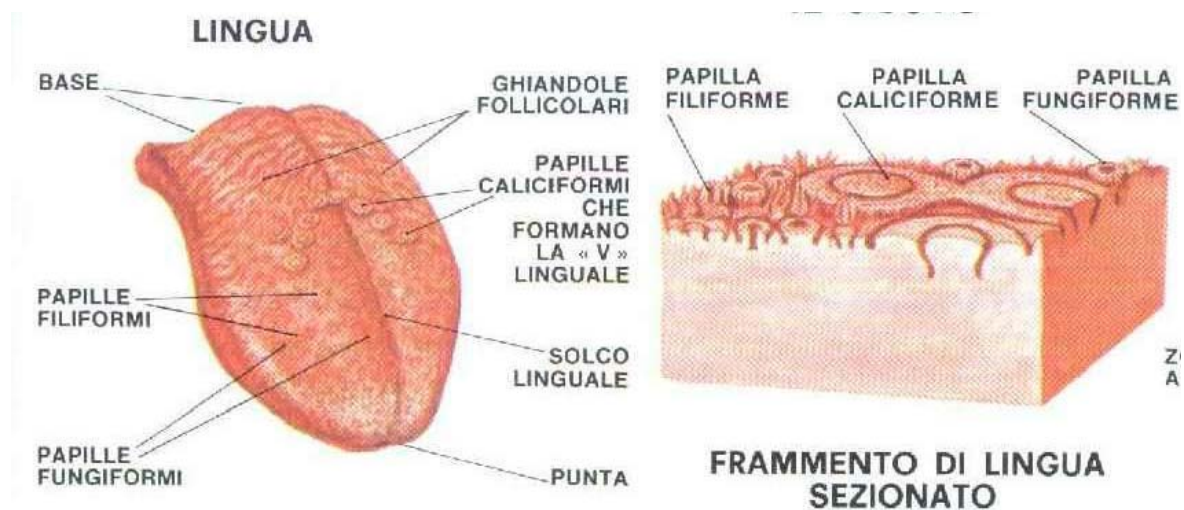


(B)

100 nm



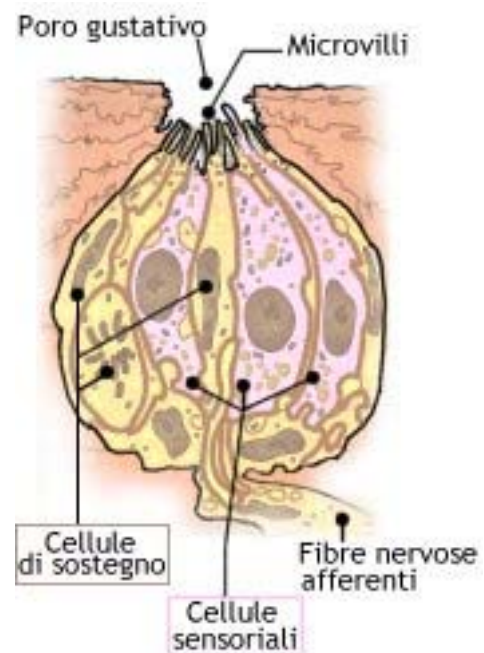
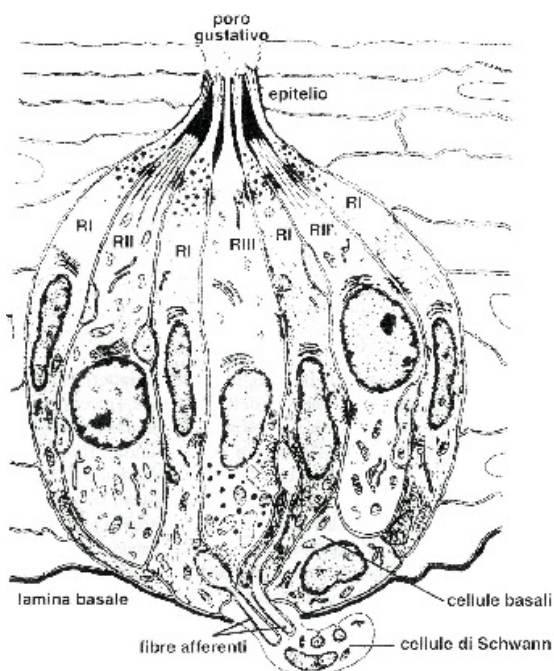
Papille gustative

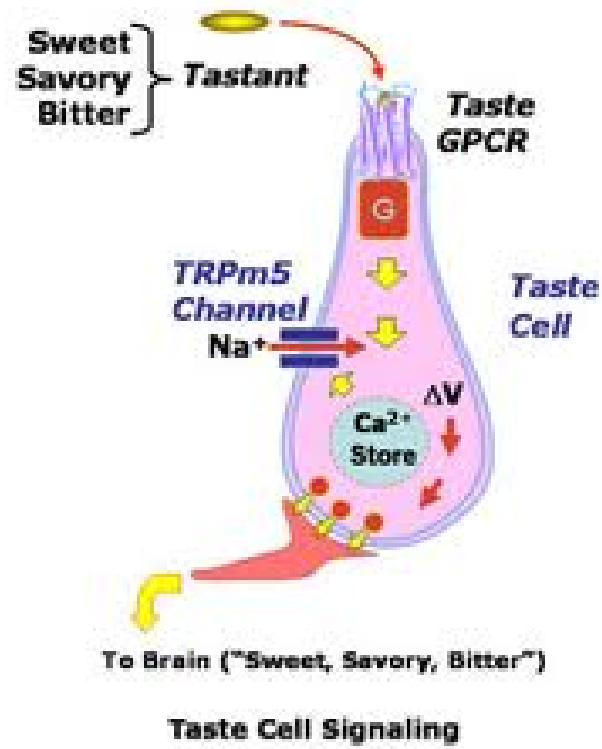


STIMOLI ESSENZIALI

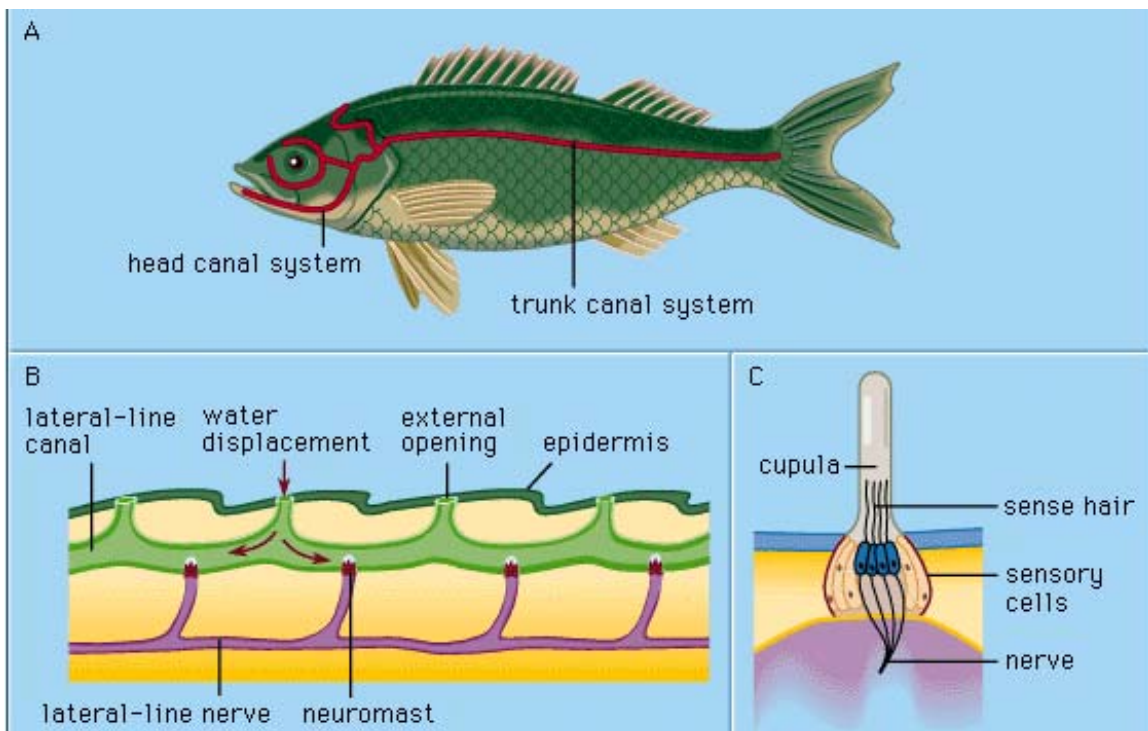
AMARO
DOLCE
ACIDO
SALATO

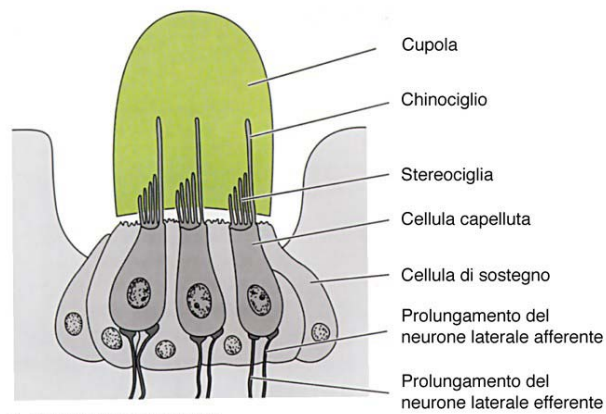
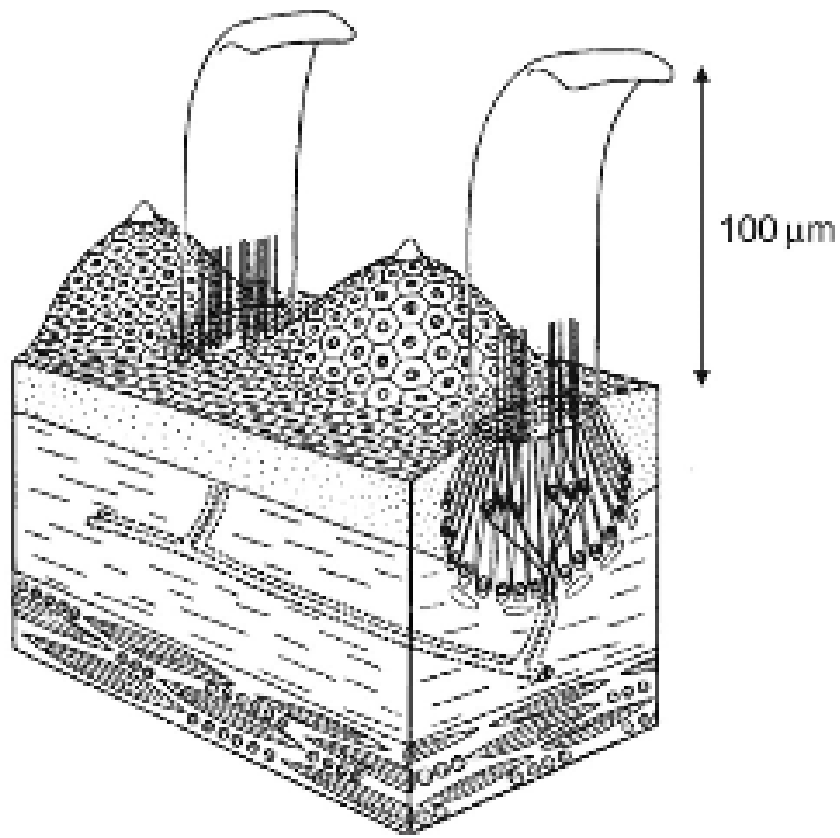
Bottoncino gustativo



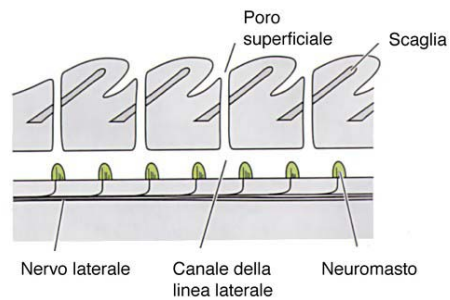


NEUROMASTI



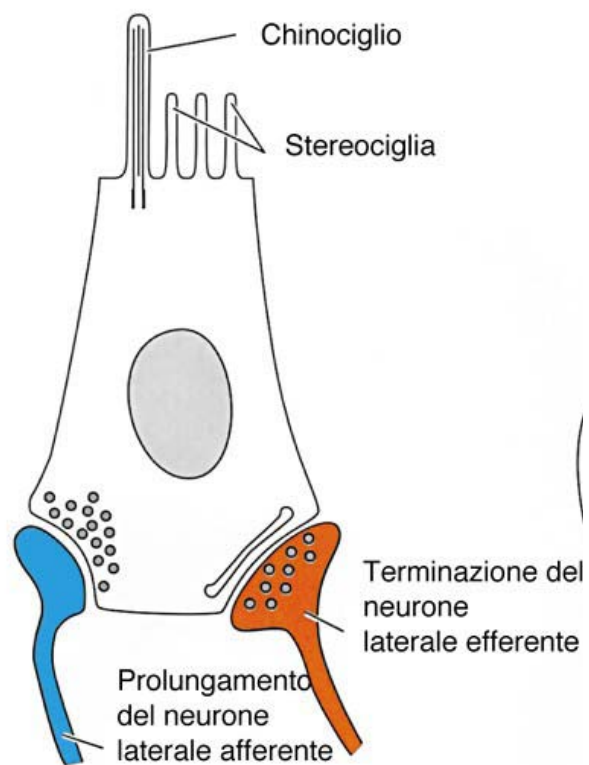
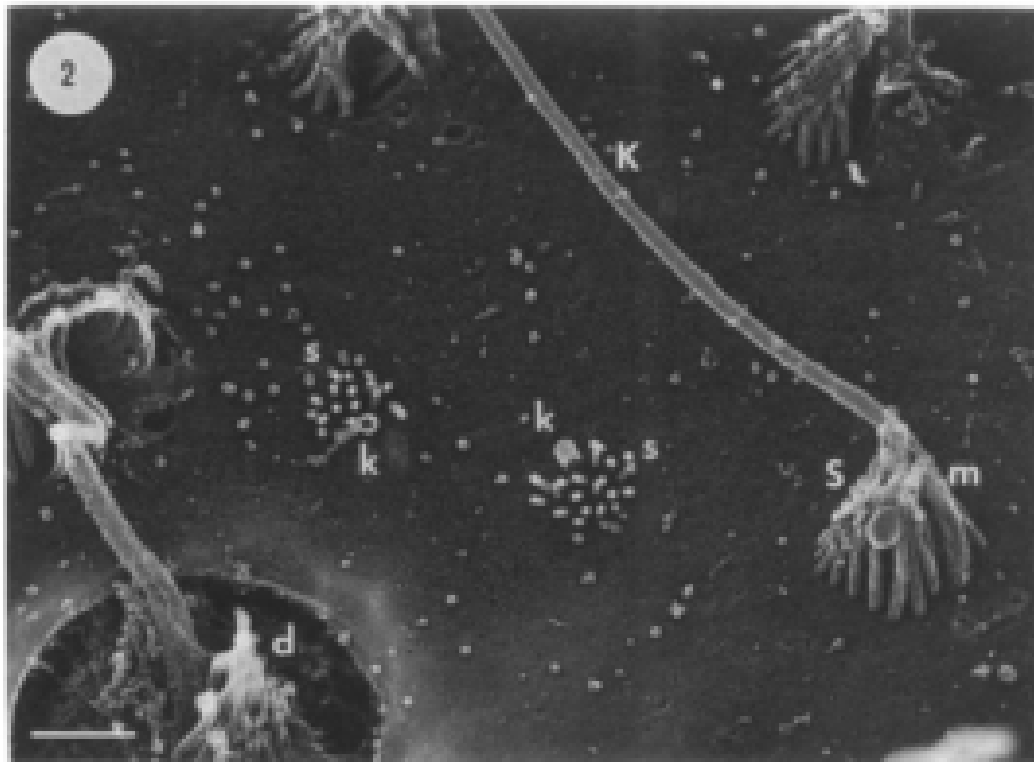


A. Neuromasto superficiale.



B. Neuromasti localizzati nel canale della linea laterale.

FIGURA 12-8



A. Cellula capelluta di un neuromasto di un canale

